



## PATIENT

Tucker Schwartz

## SPECIES

Canine

## BREED

Beagle Mix

## SEX

N

## AGE

12 y

## WEIGHT

31.6 lb

## INTERPRETED BY

Keith Blass, DVM, MS,  
DACVIM (Cardiology)

## IMAGING PERFORMED BY

Kerri Becker

## HOSPITAL NAME

Bergen County VC

## REFERRING VET

Dr. Scaglione

## INVOICE

## DATE

1/21/26

## PRESENTING CLINICAL SIGNS

New grade 3/6 murmur.

## ECHOCARDIOGRAPHIC FINDINGS

2D, M-mode, and Doppler study.

Left atrial size is normal. The mitral valve leaflets are mildly thickened, and a mild to moderate jet of eccentric mitral regurgitation is present. Left ventricular dimensions are normal. Left ventricular systolic function is hyperdynamic. The aorta and aortic valve are normal. Right atrial and right ventricular dimensions are normal. The tricuspid valve leaflets are mildly thickened, and a mild jet of tricuspid regurgitation is present. The pulmonary artery and pulmonic valve appear normal, though trace pulmonic insufficiency is present. No shunting lesions are visualized. No pericardial effusion or cardiac masses are seen.

ECG during echo: Sinus rhythm

LA - 38.1 mm  
LVIDd - 37.7 mm  
LVIDs - 19.9 mm  
FS - 47.2%  
RA - 24.9 mm  
LVOT - 1.40 m/s  
RVOT - 1.31 m/s

## ASSESSMENT/RECOMMENDATIONS

Degenerative mitral and tricuspid valve disease

This examination demonstrates regurgitation of blood across Tucker's mitral and tricuspid valves resulting from degenerative valve disease. The hemodynamic effects of the regurgitations appear to be mild at present, as Tucker does not have secondary dilation of any of his cardiac chambers, and his ventricular systolic function is well-preserved. As such, Tucker's current risk for the development of clinical signs secondary to his valvular diseases, such as coughing, exercise intolerance, syncope, labored breathing, and abdominal distension, appears to be low.

No therapy is recommended at this stage of Tucker's valvular diseases.

A recheck echocardiogram is recommended in 6 months to monitor for disease progression.



### PATIENT

Tucker Schwartz

### SPECIES

Canine

### BREED

Beagle Mix

### SEX

N

### AGE

12 y

### WEIGHT

31.6 lb

### INTERPRETED BY

Keith Blass, DVM, MS,  
DACVIM (Cardiology)

### IMAGING PERFORMED BY

Kerri Becker

### HOSPITAL NAME

Bergen County VC

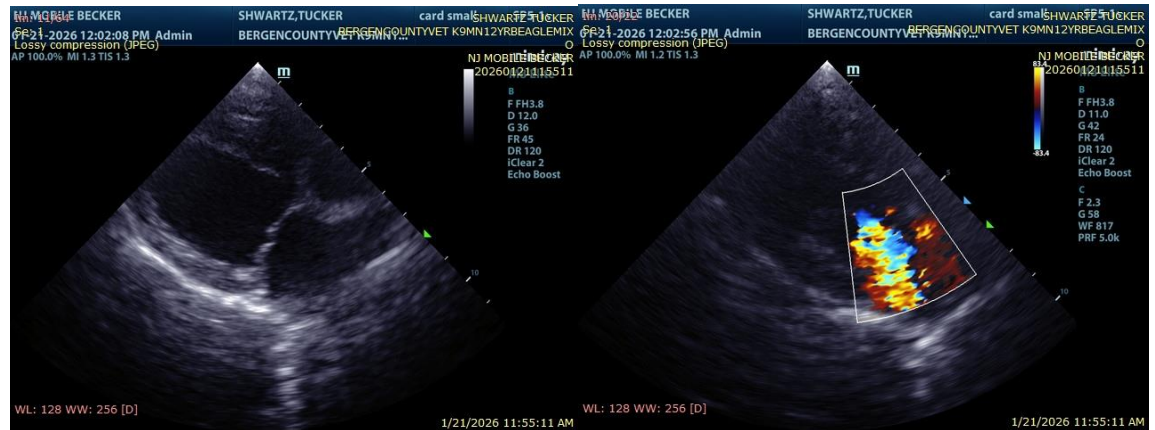
### REFERRING VET

Dr. Scaglione

### INVOICE

### DATE

1/21/26



The information and recommendations provided are based on the images presented by the referring veterinarian/sonographer. No evaluation can be communicated regarding pathology that was not visible in the image/video clips provided.

Thank you for this referral. If the clinical or image interpretation does not parallel your findings or if I can be of any further assistance please contact me.

Keith Blass, DVM, MS, DACVIM (Cardiology)

[info@SonoPath.com](mailto:info@SonoPath.com)